

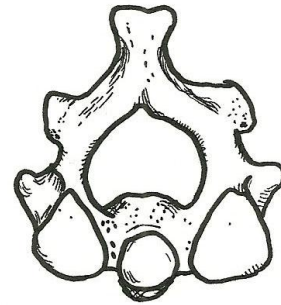
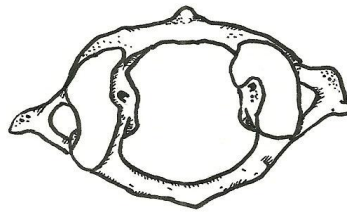
Be able to recognize whether a vertebra is cervical (C1-C7), thoracic (T1-T12), or lumbar (L1-L5), and be able to recognize atlas and axis

C1-Atlas-superior view

Atlas

C2-Axis-superior view

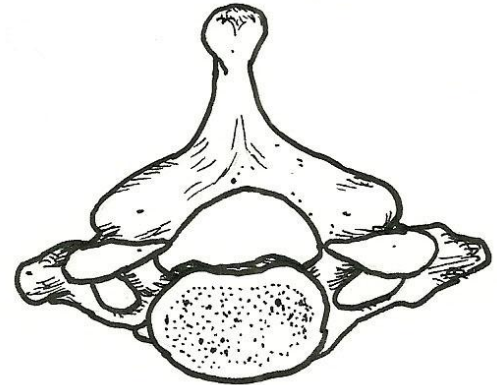
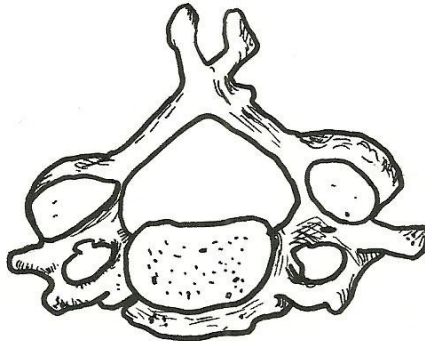
Axis



Cervical Vertebra (C5 + C7)

superior views

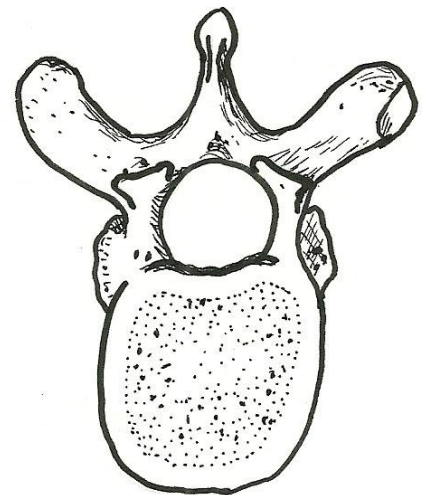
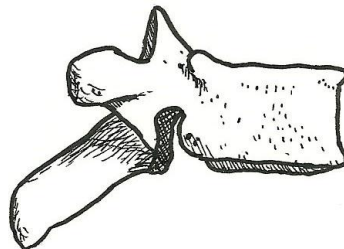
- body
- pedicle
- lamina
- vertebral foramen
- transverse process
- transverse foramen
- spinous process



Thoracic Vertebra (T7)

lateral view (of 1 and of 2)

- body
- pedicle
- transverse process
- spinous process
- superior articular process
- inferior articular process
- intervertebral foramen (between 2)



superior view

- body
- pedicle
- lamina
- vertebral foramen
- transverse process
- spinous process
- superior articular process

