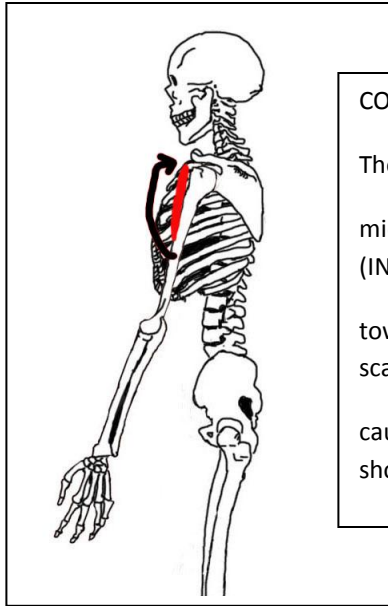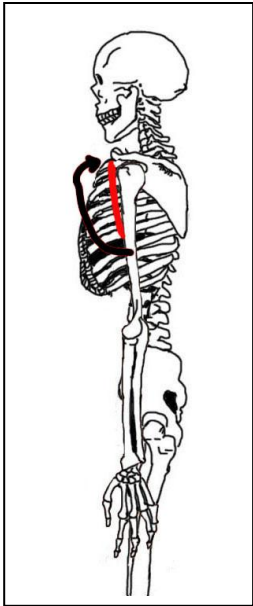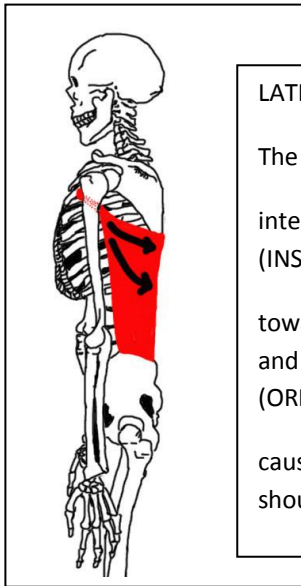
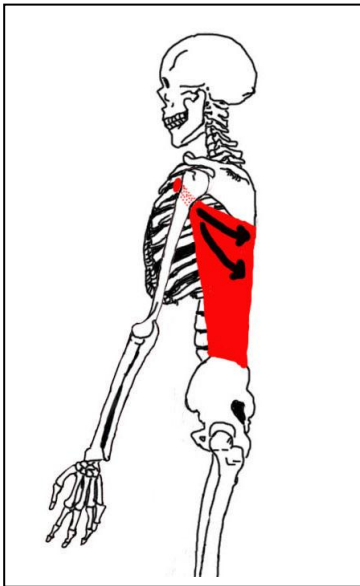


CORACOBRACHIALIS

The coracobrachialis muscle pulls the mid medial shaft of the humerus (INSERTION)

towards the coracoid process of the scapula (ORIGIN)

causing flexion of the upper limb at the shoulder (ACTION)

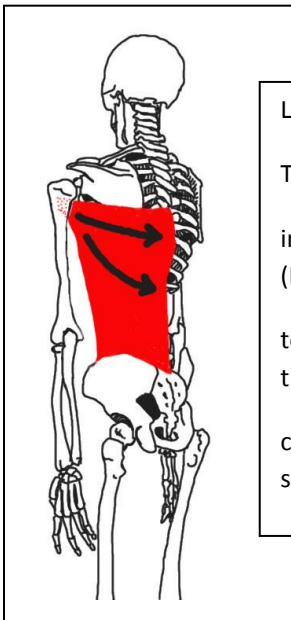
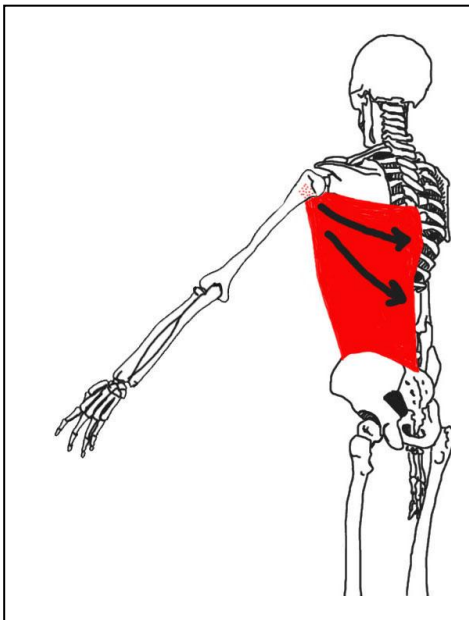


LATISSIMUS DORSI

The latissimus dorsi muscle pulls the intertubercular sulcus of the humerus (INSERTION)

towards the thoracic and lumbar vertebrae and the inferior four ribs and the iliac crest (ORIGIN)

causing extension of the upper limb at the shoulder (ACTION)



LATISSIMUS DORSI

The latissimus dorsi muscle pulls the intertubercular sulcus of the humerus (INSERTION)

towards the thoracic and lumbar vertebrae and the inferior four ribs and the iliac crest (ORIGIN)

causing adduction of the upper limb at the shoulder (ACTION)