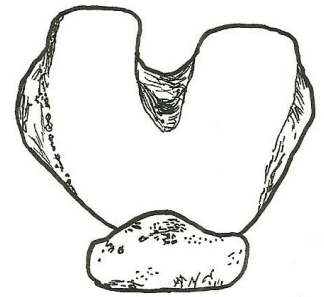
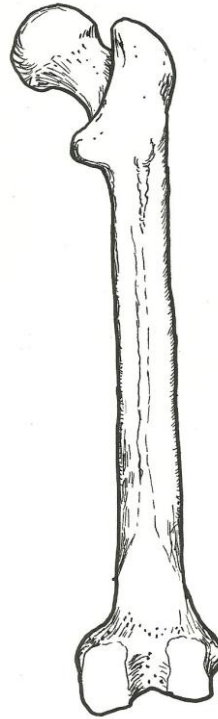
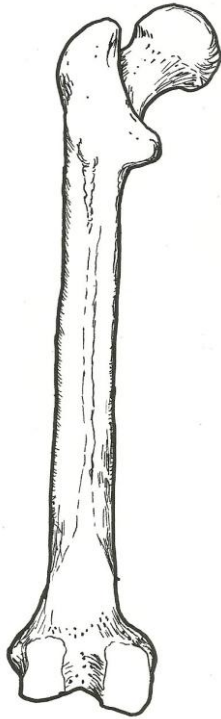


**Femur – posterior view**

head  
neck  
greater trochanter  
lesser trochanter  
gluteal tuberosity  
linea aspera  
lateral epicondyle  
medial epicondyle  
lateral condyle  
medial condyle

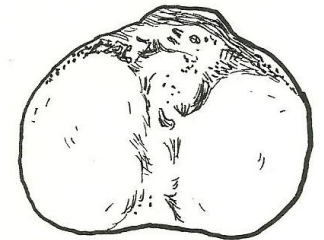
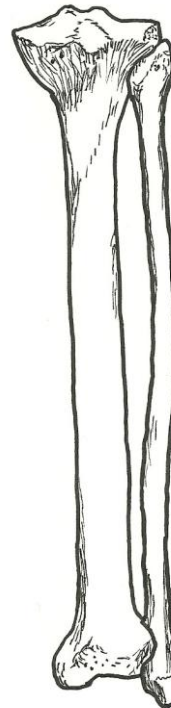


**Femur – distal end  
inferior view**

medial condyle  
lateral condyle  
patella

**Tibia – proximal end  
superior view**

medial condyle  
lateral condyle  
tibial tuberosity



**Tibia and Fibula  
posterior view**

tibia  
lateral condyle  
medial condyle  
medial malleolus  
fibula  
lateral malleolus  
proximal tibiofibular joint  
interosseous membrane  
distal tibiofibular joint

