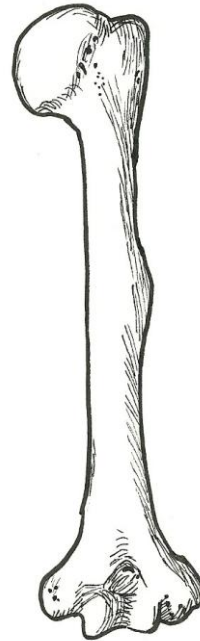


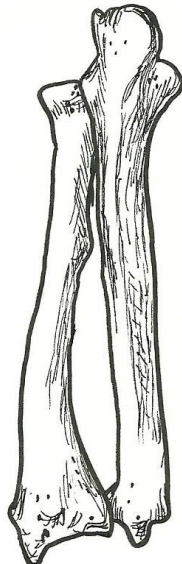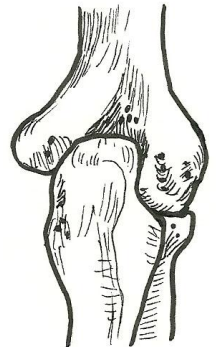
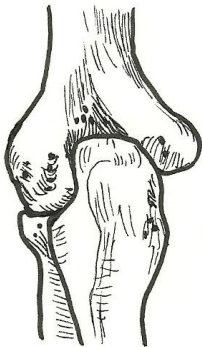
Humerus – posterior view

- head (of humerus)
- anatomical neck
- surgical neck
- greater tubercle
- deltoid tuberosity
- trochlea
- olecranon fossa
- lateral epicondyle
- medial epicondyle



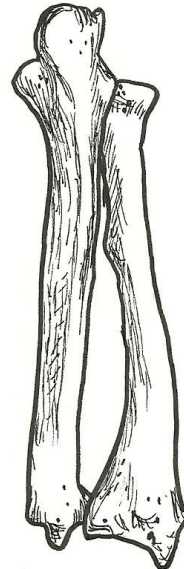Elbow joint – posterior view

- humerus
- radius
- ulna
- olecranon
- olecranon fossa
- medial epicondyle
- lateral epicondyle
- head of radius



Radius & Ulna – posterior view

- radius
 - head (of radius)
 - neck
 - styloid process
- ulna
 - olecranon
 - styloid process
- proximal radioulnar joint
- distal radioulnar joint
- interosseous membrane



Hand – dorsal (posterior) view

- radius
- ulna
- carpals
- metacarpals
 - base
 - shaft
 - head
- phalanges
 - base
 - shaft
 - head
 - proximal phalanges
 - middle phalanges
 - distal phalanges
- distal radioulnar joint
- radiocarpal joint
- intercarpal joint
- carpometacarpal joint
- metacarpophalangeal joint
- interphalangeal joint

