

**dense regular connective tissue**

**slide – fibrous tissue white**

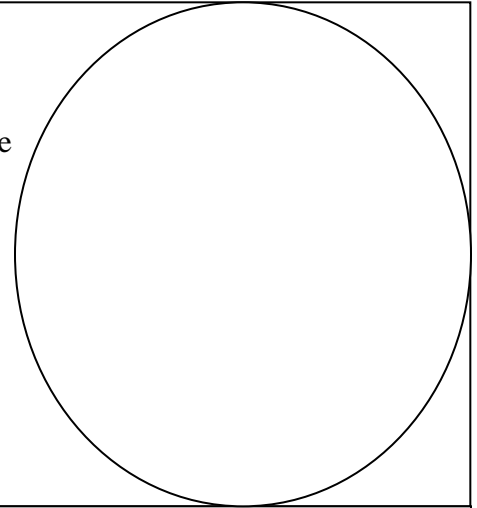
SOME slides have BOTH tendon and muscle. Be sure to focus in on the lighter colored tendon rather than the darker muscle.

**Magnification:**

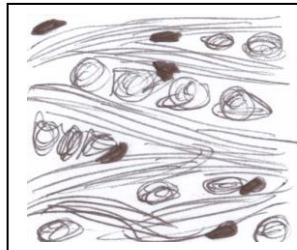
( ) eyepiece  
x( ) objective

\_\_\_\_\_

= ( ) total



**Slide Title =** \_\_\_\_\_



**dense irregular connective tissue**

**slide – skin / human / skin hair follicles**

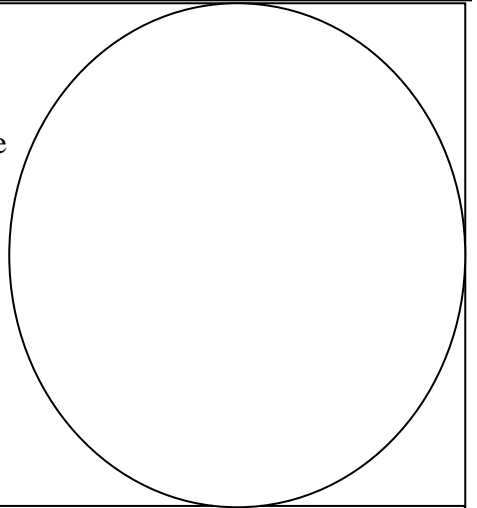
Look for the swirling red bundles *between* the hair follicles, DON'T just draw only a hair follicle or a gland.

**Magnification:**

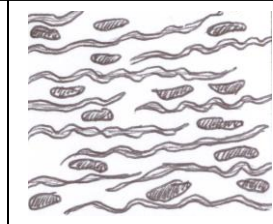

( ) eyepiece  
x( ) objective

\_\_\_\_\_

= ( ) total



**Slide Title =** \_\_\_\_\_



**elastic connective tissue**

**slide– aorta verhoeff human**

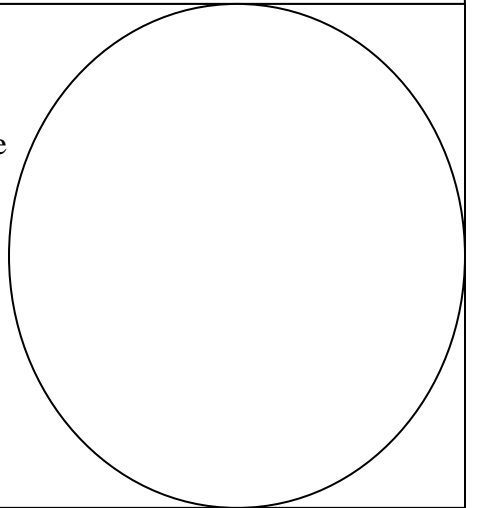
Look for wavy fibers and for cells between the fibers.

**Magnification:**

( ) eyepiece  
x( ) objective

\_\_\_\_\_

= ( ) total



**Slide Title =** \_\_\_\_\_