

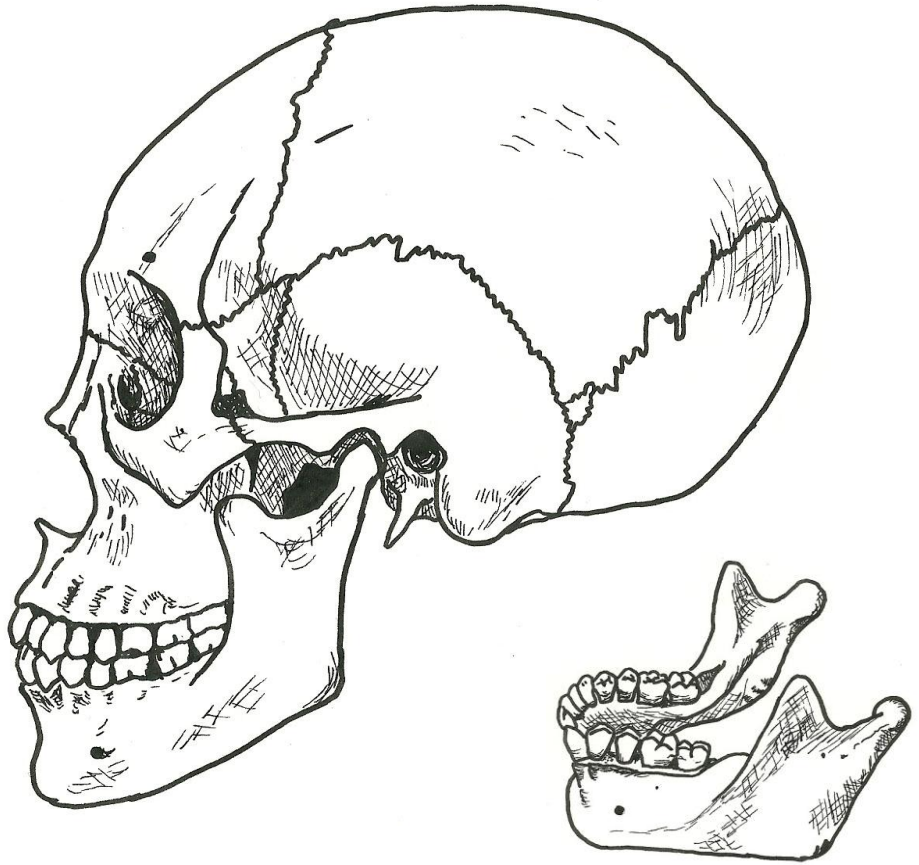
**Adult Skull (lateral view)**

**CRANIAL SKULL**

- parietal bone
- frontal bone
- temporal bone
- occipital bone
- lambdoid suture
- coronal suture
- squamous suture
- mandibular fossa
- articular tubercle
- zygomatic process
- styloid process
- mastoid process
- external auditory meatus

**FACIAL SKULL**

- zygomatic bone
- temporal process
- lacrimal bone
- nasal bone
- maxilla
- mandible
- mandibular notch
- coronoid process
- condylar process
- ramus
- body (of mandible)
- angle (of mandible)



**Mandible bone**

**FACIAL SKULL**

- mandible
- mandibular notch
- coronoid process
- condylar process
- ramus
- body (of mandible)
- angle (of mandible)

