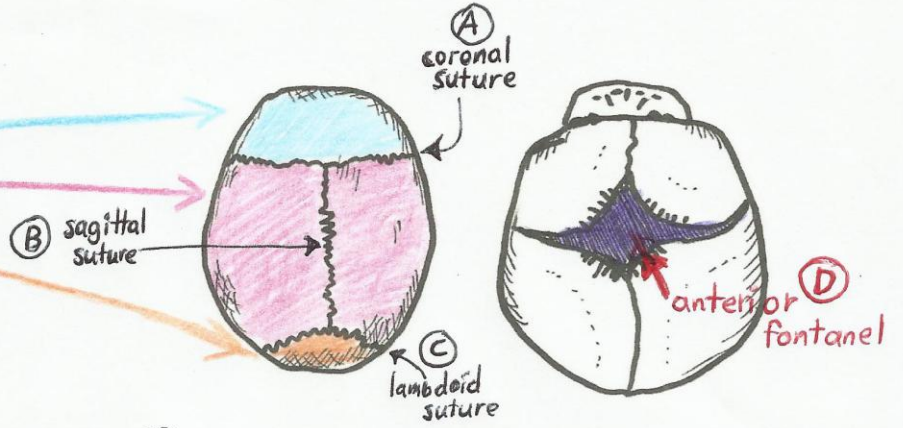


**Adult Skull (superior view)**

CRANIAL SKULL

- frontal bone
- parietal bone
- occipital bone
- A coronal suture
- B sagittal suture
- C lambdoid suture



**Fetal Skull (superior view)**

CRANIAL SKULL

- D anterior fontanel

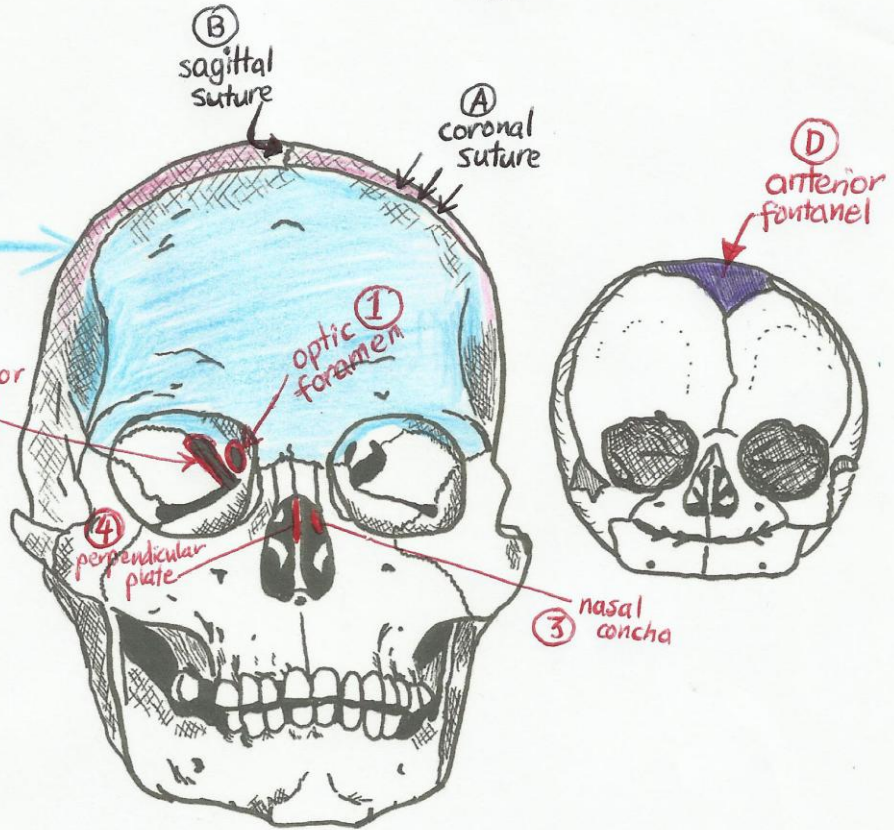
**Adult Skull (anterior view)**

CRANIAL SKULL

- frontal bone
- 1 optic foramen
- 2 superior orbital fissure
- 3 nasal concha (middle)
- 4 perpendicular plate
- A coronal suture
- B sagittal suture

- FACIAL SKULL
- zygomatic bone
  - maxilla
  - mandible
  - vomer
  - nasal bone
  - lacrimal bone
  - nasal concha (inferior)
  - inferior orbital fissure

LAB #2 (not on first quiz)



**Fetal Skull (anterior view)**

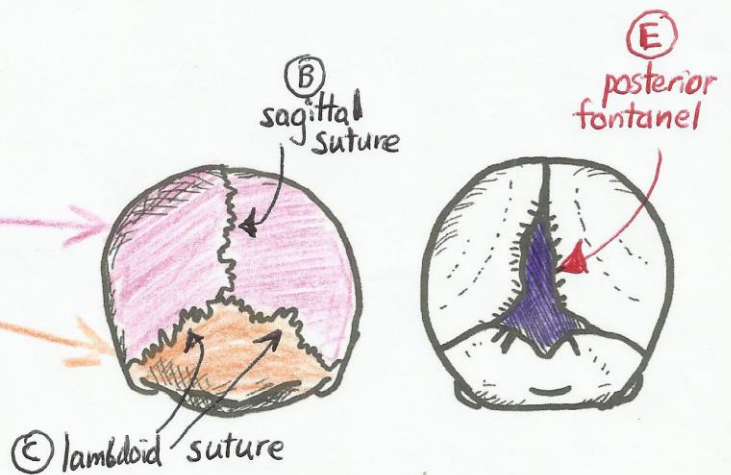
CRANIAL SKULL

- D anterior fontanel

**Adult Skull (posterior view)**

CRANIAL SKULL

- parietal bone
- occipital bone
- B sagittal suture
- C lambdoid suture



**Fetal Skull (posterior view)**

CRANIAL SKULL

- E posterior fontanel