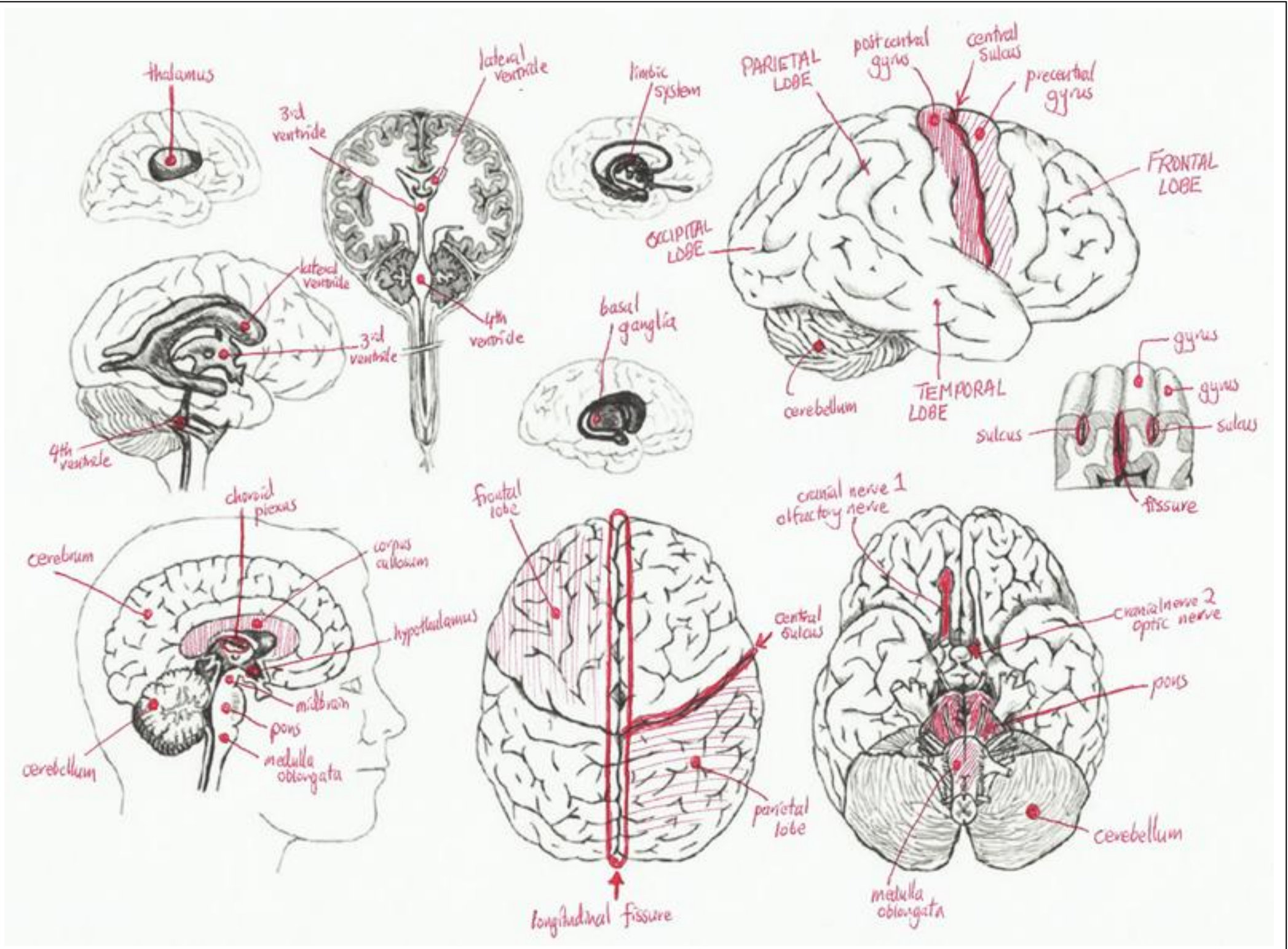
thalamus
lateral ventricle
3rd ventricle
limbic system
PARIETAL LOBE
post central gyrus
central sulcus
precentral gyrus
FRONTAL LOBE
OCCIPITAL LOBE
lateral ventricle
3rd ventricle
4th ventricle
basal ganglia
cerebellum
TEMPORAL LOBE
gyrus
gyrus
sulcus
sulcus
fissure
4th ventricle
choroid plexus
cerebrum
corpus callosum
hypothalamus
midbrain
pons
cerebellum
medulla oblongata
frontal lobe
central sulcus
parietal lobe
longitudinal fissure
cranial nerve 1 olfactory nerve
cranial nerve 2 optic nerve
pons
cerebellum
medulla oblongata