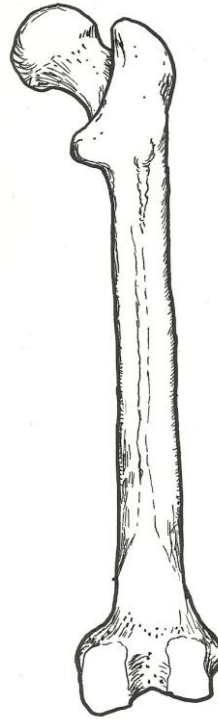
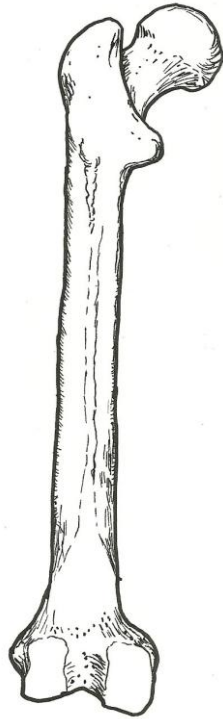


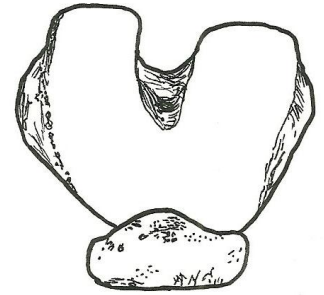
Femur – posterior view

- head
- neck
- greater trochanter
- lesser trochanter
- linea aspera
- lateral condyle
- medial condyle



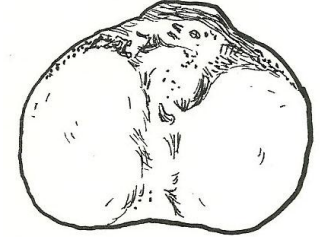
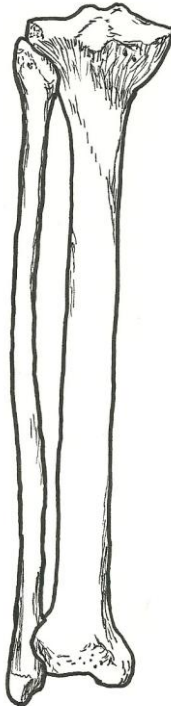
**Femur – distal end
inferior view**

- medial condyle
- lateral condyle
- patella



**Tibia – proximal end
superior view**

- medial condyle
- lateral condyle
- tibial tuberosity



**Tibia and Fibula
posterior view**

- tibia
 - lateral condyle
 - medial condyle
- fibula
- proximal tibiofibular joint
- interosseous membrane
- distal tibiofibular joint

