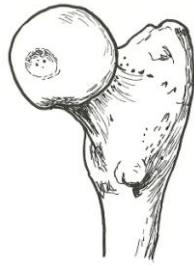


**Femur – proximal end
medial view**

head
neck
greater trochanter
lesser trochanter



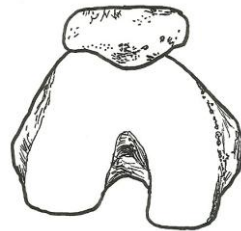
Femur – anterior view

head
neck
greater trochanter
lesser trochanter
lateral condyle
medial condyle



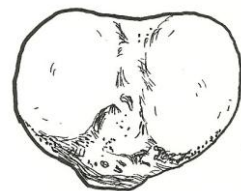**Femur – distal end
inferior view**

medial condyle
lateral condyle
patella



**Tibia – proximal end
superior view**

medial condyle
lateral condyle
tibial tuberosity



**Tibia and Fibula
anterior view**

tibia
lateral condyle
medial condyle
tibial tuberosity
fibula
proximal tibiofibular joint
interosseous membrane
distal tibiofibular joint

