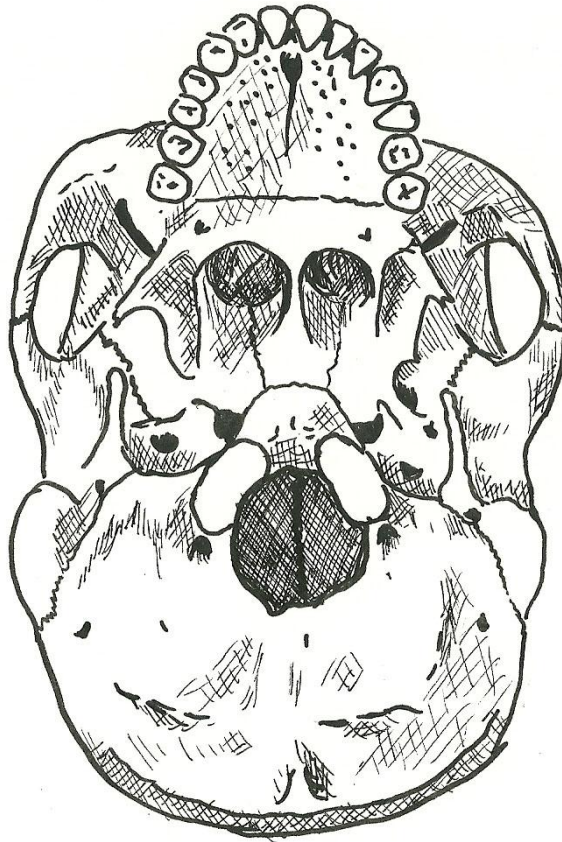


Adult Skull (inferior view)

- CRANIAL SKULL
 - sphenoid bone
 - temporal bone
 - occipital bone
 - styloid process
 - occipital condyle
 - inferior nuchal line
 - superior nuchal line
 - foramen magnum
- FACIAL SKULL
 - maxilla
 - palatine process
 - palatine bone
 - zygomatic bone
 - vomer



Adult Skull (floor of cranial cavity)

- CRANIAL SKULL
 - frontal bone
 - frontal sinus
 - ethmoid bone
 - sphenoid bone
 - temporal bone
 - occipital bone
 - crista galli
 - olfactory foramina
 - cribriform plate
 - sella turcica
 - foramen magnum

