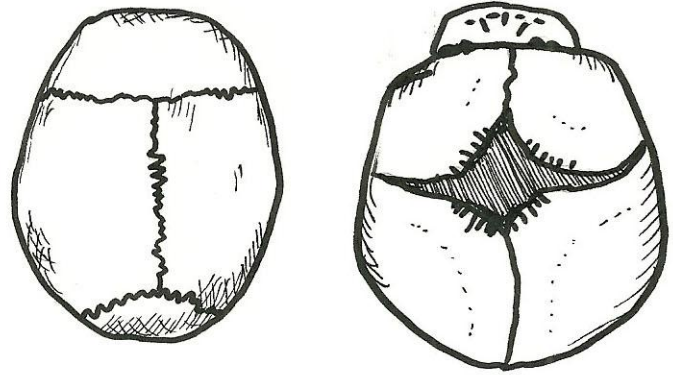


Adult Skull (superior view)

CRANIAL SKULL

- frontal bone
- parietal bone
- occipital bone
- coronal suture
- sagittal suture
- lambdoid suture



Fetal Skull (superior view)

CRANIAL SKULL

- anterior fontanel

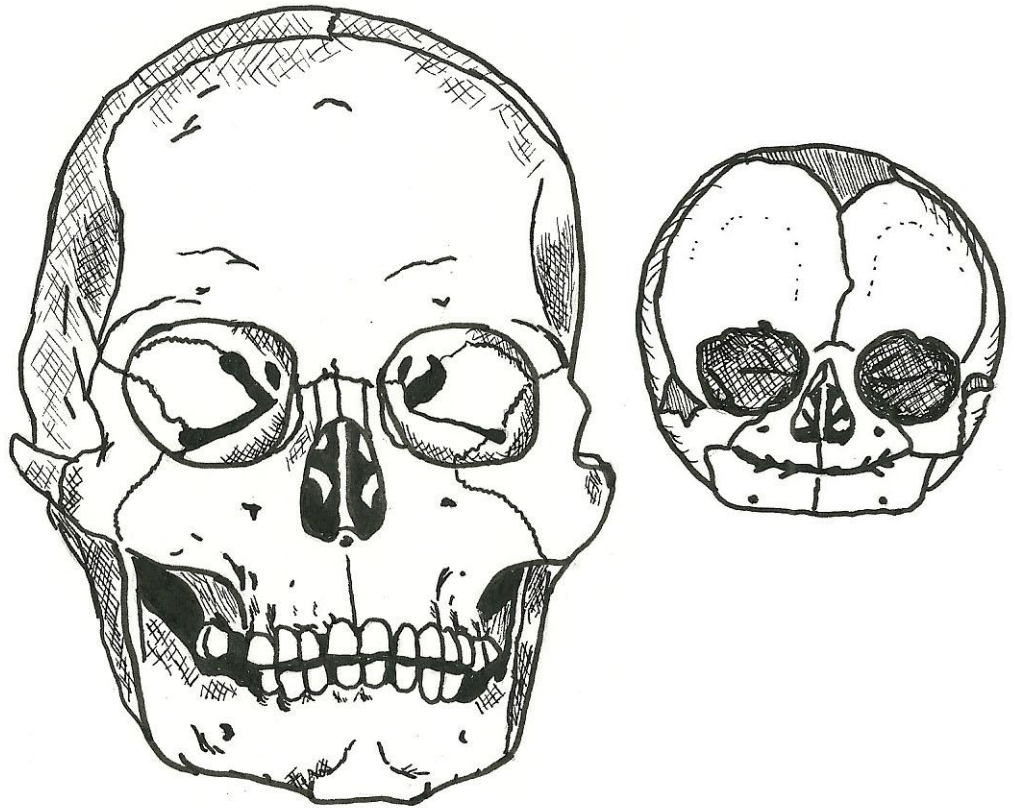
Adult Skull (anterior view)

CRANIAL SKULL

- frontal bone
- optic foramen
- superior orbital fissure
- nasal concha (middle)
- perpendicular plate
- coronal suture
- sagittal suture

FACIAL SKULL

- zygomatic bone
- maxilla
- mandible
- vomer
- nasal bone
- lacrimal bone
- nasal concha (inferior)
- inferior orbital fissure



Fetal Skull (anterior view)

CRANIAL SKULL

- anterior fontanel

Adult Skull (posterior view)

CRANIAL SKULL

- parietal bone
- occipital bone
- sagittal suture
- lambdoid suture

Fetal Skull (posterior view)

CRANIAL SKULL

- posterior fontanel

