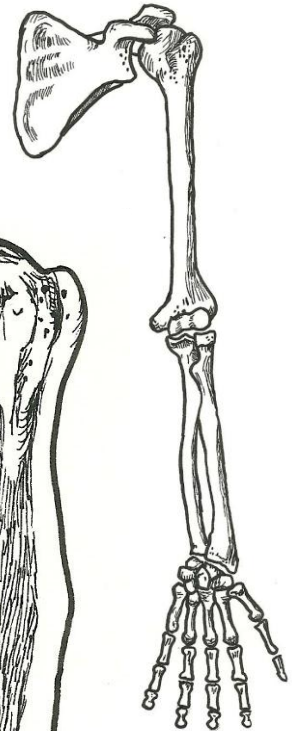


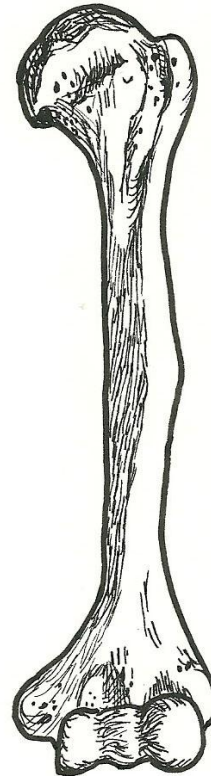
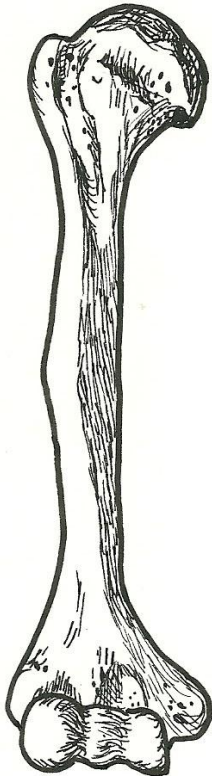
Upper Limb – anterior view

scapula
 humerus
 radius
 ulna
 carpals
 metacarpals
 phalanges
 glenohumeral joint
 proximal radioulnar joint
 distal radioulnar joint
 interosseous membrane



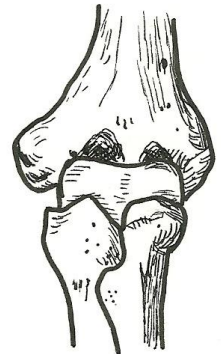
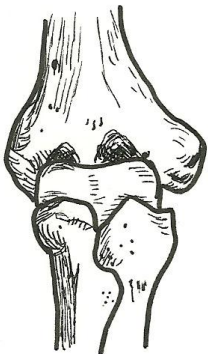
Humerus – anterior view

head
 anatomical neck
 surgical neck
 greater tubercle
 lesser tubercle
 intertubercular sulcus
 deltoid tuberosity
 capitulum
 trochlea
 radial fossa
 coronoid fossa
 lateral epicondyle
 medial epicondyle



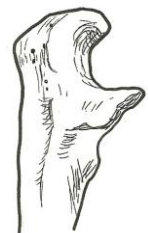
Elbow joint – anterior view

humerus
 radius
 ulna
 capitulum
 trochlea
 head (of radius)
 coronoid process
 medial epicondyle
 lateral epicondyle
 radial fossa
 coronoid fossa



Radius & Ulna – anterior view

radius
 head (of radius)
 neck
 radial tuberosity
 styloid process
 ulna
 trochlear notch
 coronoid process
 olecranon
 head (of ulna)
 styloid process
 proximal radioulnar joint
 distal radioulnar joint
 interosseous membrane



**proximal ulna
 (lateral view)**
 olecranon
 trochlear notch
 coronoid process